


Diagnostic Imaging of A2 Pulley Injuries

A Review of the Literature

William Berrigan, MD, William White, MD, Kevin Cipriano, MD, Jordan Wickstrom, PhD , Jay Smith, MD, Nelson Hager, MD

Received May 28, 2021, from the Department of Orthopaedics, Emory University School of Medicine, Atlanta, Georgia, USA (W.B.); Department of Rehabilitation Medicine, Medstar Georgetown University Hospital, Washington, District of Columbia, USA (W.W., K.C.); Department of Biomechanics, University of Nebraska at Omaha, Omaha, Nebraska, USA (J.W.); Department of Physical Medicine and Rehabilitation, Radiology, and Clinical Anatomy, Mayo Clinic, Rochester, Minnesota, USA (J.S.); and Department of Physical Medicine and Rehabilitation, Uniformed Services University of the Health Sciences, Bethesda, Maryland, USA (N.H.). Manuscript accepted for publication May 30, 2021.

The authors wish to acknowledge Michael Farrell, MD and Blynn L. Shideler III, BS for assistance with formation of figures. This work was supported in part by the Uniformed Services University, Department of Physical Medicine & Rehabilitation, Musculoskeletal Injury Rehabilitation Research for Operational Readiness (MIRROR) (HU00011920011).

Address correspondence to Nelson Hager, MD, MS, Uniformed Services University of the Health Sciences, Department of Physical Medicine and Rehabilitation, 4301 Jones Bridge Road, Bethesda, MD 20814-4799.

E-mail: nelson.hager@usuhs.edu

Abbreviations

CT, computed tomography; DIP, distal interphalangeal; MRI, magnetic resonance imaging; PIP, proximal interphalangeal; TP, tendon to phalanx; US, ultrasound

doi:10.1002/jum.15796

This is an open access article under the terms of the Creative Commons Attribution-NonCommercial-NoDerivs License, which permits use and distribution in any medium, provided the original work is properly cited, the use is non-commercial and no modifications or adaptations are made.

Injury to the A2 pulley is caused by high eccentric forces on the flexor-tendon-pulley system. Accurate diagnosis is necessary to identify the most appropriate treatment options. This review summarizes the literature with respect to using ultrasound (US) to diagnose A2 pulley injuries, compares ultrasound to magnetic resonance imaging and computed tomography, and identifies current knowledge gaps. The results suggest that US should be used as the primary imaging modality given high accuracy, relatively low cost, ease of access, and dynamic imaging capabilities. Manual resistance is beneficial to accentuate bowstringing, but further research is needed to determine best positioning for evaluation.

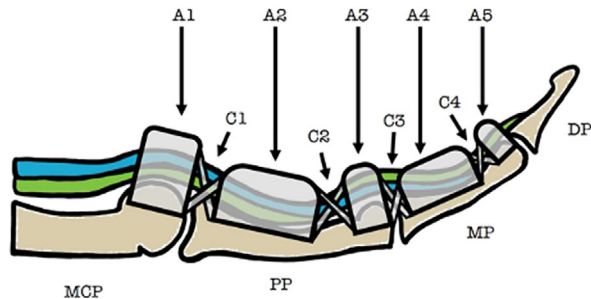
Key Words—CT; finger injury; MRI; rock climbing; US

The annular pulleys are fibrous envelopes that enhance flexor tendon functions by holding the tendons against the phalanges. Of the five pulleys, the A2 pulley is the thickest and strongest, and has an average length of 16.3 mm.¹ Anatomically, the A2 pulley stretches from the cranial part of the proximal phalanx to the junction of the proximal two-thirds and distal-third of the proximal phalanx (Figure 1). When the A2 pulley is significantly injured, bowstringing of the flexor tendons occurs, which can lead to a range of motion loss and reduced finger function. Bowstringing is a result of the flexor tendon gaining an increased mechanical advantage over the extensors, causing the tendon to separate from the phalanx and restrict digit extension.²

Biomechanical analysis has shown that injury to the A2 pulley likely occurs when the pulley is eccentrically loaded, resulting in high tensile forces between the pulley and tendon.³ Consequently, eccentric flexor tendon loading is generally considered to be one of the greatest risk factors for A2 pulley injury.³ A2 pulley injuries have been reported in rock climbers, baseball players, bowlers, and other persons who engage in activities that involve a sudden extension force applied to an acutely flexed digit.⁴⁻⁷ Pulley injuries have also been frequently reported in patients who have received multiple steroid injections near the pulley site.⁸ Cadaver studies have further investigated the biomechanics of loading within the pulley system to determine which pulley is most prone to injury, with one study reporting that the A2 pulley is most likely to rupture, followed by the A3, A4, and A1 pulleys.⁹

Rock climbing has the highest incidence of A2 pulley injuries of all sports.¹⁰ A survey of competitive rock climbers in the United States found that 26% of climbers were found to have flexor pulley injuries involving A2.⁴ This is because climbers will often support

Figure 1. Sagittal depiction of the anatomy of the finger flexor pulley system. The flexor digitorum superficialis (blue) and flexor digitorum profundus (green) are displayed. Annular pulleys are represented using A1–A5 and cruciate pulleys using C1–C4. MCP, metacarpophalangeal joint; PP, proximal phalanx; MP, middle phalanx; DP, distal phalanx.



their entire body weight using one or two fingers in a flexed position, imparting significant stress on the pulleys. In addition, climbers will sometimes use a crimp grip (Figure 2) to successfully latch on to small surface areas while climbing. The crimp grip positions the proximal interphalangeal (PIP) joint at 90+ degrees of flexion and the distal interphalangeal (DIP) joint in maximal hyperextension,¹¹ which places 36 times more force on the A2 pulley than a standard slope grip.¹² This underlying tension has been described to exceed the threshold for A2 pulley rupture.¹²

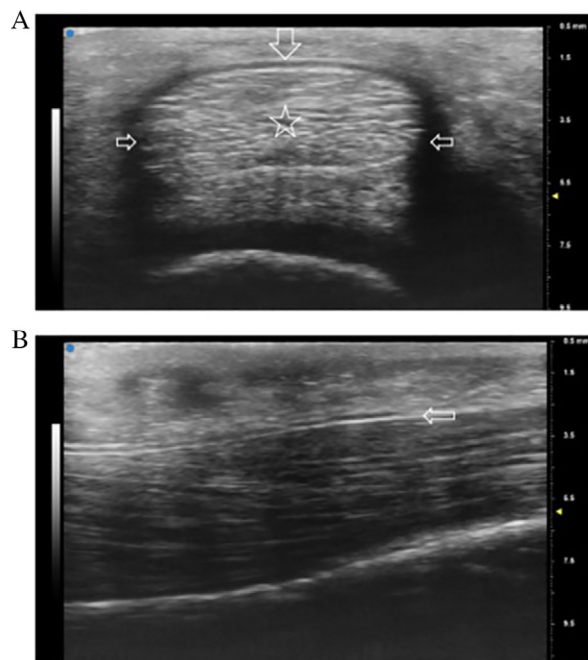
Clinically, A2 pulley tears can present either acutely or chronically and range in severity from small, partial tears to large, complete tears. Acute pulley tears can involve a sudden sharp pain that occurs during activity with an audible “pop” followed by finger swelling.³ Chronic injuries are caused by repetitive microtrauma to the pulley, which can lead to symptoms of focal tenderness and pain while gripping. Bowstringing is generally considered to be indicative of a major A2 pulley injury as it typically results in cosmetic and functional deficiencies.¹³ The clinical diagnosis of bowstringing can be particularly challenging because pain and swelling can obscure bowstringing, and lower severity injuries may present with more subtle bowstringing.¹³ Therefore, clinicians must often rely on advanced imaging to make an accurate diagnosis and determine the best available treatment options, which may range from observation to surgical reconstruction. Several modalities have been proposed for this purpose, including ultrasound (US), magnetic resonance imaging (MRI), and computed tomography (CT).

Figure 2. Representation of crimp grip of the fingers in a typical climbing position.



US is a high-resolution, accessible, cost-effective musculoskeletal imaging modality that can be used to visualize the soft tissue structures of the fingers as well as the adjacent bony surfaces (Figure 3).¹⁴ It is the only imaging modality that offers the ability to dynamically evaluate the pulley–tendon complex and easily compare the affected versus contralateral side.¹³ For example, in addition to static imaging, the examiner can use real-time motion of the flexor–tendon–pulley system to differentiate it from surrounding structures and better characterize A2 pulley injuries. Specifically, resisted finger flexion can dynamically accentuate bowstringing, and the extent of bowstringing can be compared to the contralateral side.¹⁴ Similar to US, MRI also provides excellent visualization of the A2 pulley and can identify indirect signs of A2 pulley injury such as edema and an increased tendon to phalanx (TP) distance. However, unlike US, MRI is more costly, less readily available, and does not provide the ability to perform dynamic testing. Static forces may be applied during MRI scan, but real-time motion assessment is generally precluded by motion artifact.^{15,16} It can also be difficult to visualize tears on routine sagittal MRI images depending on the size of the cuts, whereas US could more feasibly capture such images. CT shares many of the challenges of MRI including relatively high cost and the absence of dynamic imaging capabilities. Although CT does allow for exceptional visualization of osseous anatomy, it is not as detailed as US and MRI when imaging soft tissue structures.

Figure 3. Normal annular A2 pulley depicted with a 20 to 46 MHz transducer (VisualSonics VEO MD). **A**, Transverse ultrasound image obtained over the proximal phalanx demonstrating the A2 pulley as a thin band surrounding the flexor tendons. Note its relatively hyperechoic appearance on the volar portion (top arrow pointing down) and relatively hypoechoic appearance on both sides of the tendon as a result of anisotropy (middle arrows pointing inward). **B**, Longitudinal ultrasound image of the A2 pulley depicting the leading edge (arrow) over the proximal phalanx with the flexor tendons underneath (right = distal).



Given that US provides a unique blend of high resolution and dynamic imaging, it is not surprising that US has been used more commonly than MRI and CT to evaluate A2 pulley injuries. The primary purpose of this review is to summarize the clinical and cadaveric US studies, compare methods and findings against the other primary modalities (MRI, CT), and acknowledge research gaps that may best aid clinicians in pulley injury diagnoses.

Methods and Results

A literature search was conducted in May 2021 in the MEDLINE/PubMed database on studies published up until the search date. Searches were performed

using a variation of the terms “A2 pulley,” “bowstringing,” and “pulley rupture.” Only one search limitation was applied—language was restricted to English only. The searches yielded a combined 690 results. Articles were excluded if they did not mention the A2 pulley or did not include US, MRI, or CT. Accordingly, 607 articles were excluded during title and abstract review, leaving 83 articles to move on to full-text review. An additional 61 articles were excluded during full-text review, leaving 22 articles to be included in this review for data extraction. Of the 22 articles, 12 included US only,^{14,17–27} 6 MRI only,^{28–33} and 1 CT only,³⁴ with 3 including a combination of imaging methods (2 articles including US and MRI^{35,36}; 1 article including US, MRI, and CT¹⁵). Sample demographics are provided in Table 1 and data extraction results in Table 2, with both tables organized into two sections: cadaver studies and clinical (non-cadaver) studies.

Ultrasound (US)

US was the most common form of imaging used to evaluate A2 pulley injuries. Out of 15 US studies, 4 (27%) evaluated A2 injuries in cadaver models, 9 (60%) in rock climbers, and 2 (13%) in healthy volunteers. Each study evaluated the A2 pulley both statically and dynamically. Sensitivity and specificity for ultrasound were reported in 4 studies (27%, 2 clinical and 2 cadaveric), with sensitivities ranging from 0.94 to 1.00 and specificities ranging from 0.94 to 1.00, when compared with surgical visualization of the tear, MRI, and/or dissection (see Table 2).

Multiple qualitative and quantitative measures for diagnosis were used. Qualitatively, in both clinical and cadaveric studies, A2 pulley injuries were generally identified by an absence of the pulley within the sagittal plane and/or a tendinous gap during resisted flexion (bowstringing). In clinical studies, injuries were also identified by one or more of the following factors: (1) fluid along the pulley or within the flexor tendon sheath, (2) a flexor tendon sheath cyst, (3) presence of fibrous tissue, (4) PIP or DIP joint fluid, or (5) irregular thickening of the A2 pulley (Figure 4). In an effort to more precisely characterize the degree of pulley disruption, quantitative measures were performed in 7 studies (47%, 4 clinical and 3 cadaveric) by specifically measuring TP distance with defined cutoff values (see example in Figure 5).

Table 1. Demographics Table

Authors	Year	Experimental Group					Control Group
		Experimental Group	Climbing Experience (Years Climbing)	N Subjects (Male: Female)	N Fingers	Mean Age (Range) in Years	N Fingers
<i>Cadaver studies</i>							
Hauger et al. ¹⁵	2000	Cadavers	N/A	4 (3:1)	24	73.5 (68–78)	N/A
Leeffang & Coert ¹⁷	2014	Cadavers	N/A	8 (NS)	24	76 (73–82)	N/A
Bayer et al. ²⁸	2015	Cadavers	N/A	10 (7:3)	21	75.5 (47–85)	N/A
Schoffl et al. ¹⁸	2017	Cadavers	N/A	10 (6:4)	34	75.5 (NS)	N/A
Schoffl et al. ¹⁹	2018	Cadavers	N/A	9 (0:9)	18	73.2 (NS)	N/A
<i>Clinical studies</i>							
Parellada et al. ²⁹	1996	HV	N/A	3 (3:0)	3	NS (23–59)	N/A
Le Viet et al. ³⁴	1996	RC; MI	NS	7 (7:0)	14*	40 (NS); 38 (NS)	N/A
Gabl et al. ³⁰	1998	RC	6–10 UIAA (NS)	13 (12:1)	13	27 (20–51)	N/A
Bodner et al. ³⁵	1999	RC; MI	NS	32 (32:0)	64*	25 (18–42)	40
Klauser et al. ²⁰	1999	RC	7–11 UIAA (5–25)	34 (29:5)	136	29.7 (21–54)	80
Martinoli et al. ³⁶	2000	RC	NS	16 (16:0)	19*	27 (22–37)	40
Klauser et al. ²¹	2000	RC	8–11 UIAA (5–16)	52 (NS)	208	29.7 (NS)	80
Klauser et al. ¹⁴	2002	RC	8–11 UIAA (3–12)	64 (NS)	256	21.7 (18–35)	N/A
Schoffl et al. ²²	2006	RC	8.53 ± 1.11 UIAA (NS)	21 (19:2)	27	34 (22–59)	N/A
Guntern et al. ³¹	2007	RC	6b–8c + French system (NS)	8 (7:1)	28	32.5 (19–43)	N/A
Bassemir et al. ²³	2015	HV	NS	200 (100:100)	1600*	41.1 (NS)	N/A
Schneeberger & Schweizer ²⁴	2016	RC	On-sight 787, redpoint 8.44 (1–30)	45 (NS)	47	33.4 (21.8–56.2)	N/A
Reissner et al. ²⁵	2018	HV	N/A	10 (6:4)	20	33 (18–60)	N/A
Hoff & Greenberg ³²	2018	HV	N/A	1 (NS)	2	NS	N/A
Schellhammer & Vantorre ³³	2019	RC; HV	NS	3 (3:0); 14 (9:5)	22	NS	N/A
Iruretagoiena-Urbieteta et al. ²⁶	2020	RC	NS	29 (NS)	58	33 (22–41)	20*
Scheibler, Janig, & Schweizer ²⁷	2021	RC; MI	6c–8b French system (NS)	11 (9:2)	12	39 (25–55)	N/A

HV, healthy volunteers; MI, miscellaneous injury; N/A, not applicable (not included in study); NS, not stated (not specified in study). RC, Rock climbers; UIAA, Union Internationale des Associations d'Alpinisme.

*Estimated based on descriptions in the paper.

Methods varied in terms of how bowstringing and TP distance were evaluated, with 6 studies (40%, 5 clinical and 1 cadaveric) that measured from the midpoint of the proximal phalanx without specifically stating how this was determined, and 3 studies (20%, 2 clinical and 1 cadaveric) that defined particular points between 10 and 20 mm from the base of the proximal phalanx (which included the midpoint). All 15 studies (100%) evaluated bowstringing in the long axis to the tendon with only 7 studies (47%) also investigating bowstringing in the short axis.

Regarding positioning of the fingers, 14 of the 15 studies (93%) used provocative positioning to stress the A2 pulley and accentuate bowstringing. The PIP and DIP were most often placed in flexion against resistance. Across all four US cadaver studies,

the PIP was placed in at least 15° flexion and the DIP in at least 10° flexion. In the 11 clinical studies, the most common position was with the PIP in at least 40° (55%) and DIP in at least 10° (64%) of flexion.

Magnetic Resonance Imaging (MRI)

MRI was the second most common imaging method used to evaluate A2 pulley injuries. Out of 9 total MRI studies, A2 injuries were evaluated in 2 studies (22%) in cadaver models, 5 studies (56%) in rock climbers, and 3 studies (33%) in healthy volunteers (note: one study examined rock climbers and healthy volunteers). Sensitivity and specificity for MRI were reported in 3 studies (33%, 2 clinical and 1 cadaveric), with sensitivities ranging from 0.79 to 1.00 and specificities ranging from 0.86 to 1.00, when compared

Table 2. Summary of Studies Using US, MRI, and CT in Diagnostics of A2 Pulley Injuries

Authors	Year	Imaging Modality	Clinical System	Finger Positioning	Resistance Applied	Diagnostic Criteria	TP Location/ Measurement	Sensitivity/ Specificity
<i>Cadaver studies</i> Hauger et al. ¹⁵	2000	CT	2 mm slices; 1 mm increments	MCP: full extension PIP: 60° flexion DIP: 10° flexion	500 g weight with traction	Complete tear: 2–5 mm Incomplete tear: 0–3 mm Combined tear: 5–8 mm	Junction of proximal two-thirds and distal one-third of the proximal phalanx	NT
		MRI	1.5-T with a phased array wrist coil	MCP: full extension PIP: 60° flexion DIP: 10° flexion	500 g weight with traction	Complete tear: 2–5 mm Incomplete tear: 0–3 mm Combined tear: 5–8 mm	Junction of proximal two-thirds and distal one-third of the proximal phalanx	NT
		US	12 MHz transducer	MCP: full extension PIP: 60° flexion DIP: 10° flexion	500 g weight with traction and simultaneous counter-pressure at the fingertip	Complete tear: 2–5 mm Incomplete tear: 0–3 mm Combined tear: 5–8 mm	Junction of proximal two-thirds and distal one-third of the proximal phalanx	NT
Leefiang & Coert ¹⁷	2014	US	Frequency band 20–60 MHz, center frequency 40 MHz transducer	MCP: 15° flexion PIP: 15° flexion DIP: 15° flexion	FDP loaded to 100 N, FDS preloaded to 5 N	Area between flexor tendon and palmar side of proximal phalanx	10 mm distal to MCP; Size of area (mm ²) between proximal phalanx and flexor tendon	NT
Bayer et al. ²⁸	2015	MRI	1.5 T with a dedicated eight channel orthopedic foot coil	Crimp Grip and Neutral PIP: full available flexion	10 N–1.0 kg weight attached to a pulley system to the FDS and FDP	*Complete tears: 2.29 ± 1.82 mm (crimp grip) 1.10 ± 0.67 mm (neutral)	50% length of the proximal phalanx >5 mm	.93/1.0 in crimp and .79/.86 in neutral dissection
Schoff et al. ¹⁸	2017	US	14 MHz transducer	MCP: NS PIP: full available flexion	10 N flexor tendons	Complete tear: >1.9 mm	Over A2 pulley	1.0/.94 Dissection
Schoff et al. ¹⁹	2018	US	18 MHz transducer	DIP: up to 30° flexion MCP: NS PIP: 30° flexion DIP: full available flexion	10 N flexor tendons	Complete tear: >2 mm	Middle of proximal phalanx	.94/1.0 Dissection
<i>Clinical studies</i> Parellada et al. ²⁹	1996	MRI	1.5 T	Finger at full extension and 30–45° flexion ^a MCP: NS	None	Bowstringing ^b	NT	NT
Le Viet et al. ³⁴	1996	CT	1.5 mm slices		Manual NS ^c	Bowstringing	NT	NT

(Continues)

Table 2. Continued

Authors	Year	Imaging Modality	Clinical System	Finger Positioning	Resistance Applied	Diagnostic Criteria	TP Location/ Measurement	Sensitivity/ Specificity
Gabl et al. ³⁰	1998	MRI	1.5 T with surface coil	PIP: flexion DIP: extension MCP: full extension PIP: 60° flexion DIP: 10° flexion	Manual Subject	Complete tear: Bowstringing from PIP joint to base of proximal phalanx Incomplete tear: Bowstringing less than to base of proximal phalanx Complete tear: ≥3 mm extended, ≥5 mm flexed	NT	NT
Bodner et al. ³⁵	1999	MRI	1.5 T with surface coil	MCP: NS PIP: 40° flexion DIP: 10° flexion	Manual subject	Complete tear: ≥3 mm extended, ≥5 mm flexed	Midpart of proximal phalanx, at bony attachment of the check rein ligament Midpart of proximal phalanx, at bony attachment of the check rein ligament	1.0/1.0 Surgical visualization ^d 1.0/1.0 Surgical Visualization
Klauser et al. ²⁰	1999	US	10 MHz transducer	MCP: NS PIP: 40° flexion DIP: 10° flexion	Manual examiner	Complete tear: >3 cm at rest, >.5 cm forced flexion Bowstringing Tenosynovitis Tendon and pulley thickening Tendon gliding Cysts/fibrous tissue Fluid collection	NS	NT
Martinoli et al. ³⁶	2000	MRI	MRI: 2 T with surface coil or a dedicated extremity coil US: 12–5 MHz and 10–13 MHz transducers	45° flexion	Manual Examiner	Bowstringing Synovial sheath effusion	At the level of the proximal phalanx/pulley	NT
Klauser et al. ²¹	2000	US	13–5 MHz transducer	45° flexion MCP: extension PIP: 40° flexion DIP: 10° flexion	Manual Examiner	Thickened hypoechoic pulley Bowstringing Tendon thickening Tendon sheath cyst Fibrous tissue Fluid collection	At the level of the base of the proximal phalanx in the area of the A2 pulley	NT

Table 2. Continued

Authors	Year	Imaging Modality	Clinical System	Finger Positioning	Resistance Applied	Diagnostic Criteria	TP Location/ Measurement	Sensitivity/ Specificity
Klauser et al. ¹⁴	2002	US	12 MHz transducer	MCP: extension PIP: 40° flexion DIP: 10° flexion	Manual Examiner	Complete tear: ≥3 mm Incomplete tear: <3 mm Combined tear (A2 + A3): ≥5 mm	15–20 mm from the base of the proximal phalanx where the flexor tendon lies close to the phalanx	.98/1.0 MRI
Schoff et al. ²²	2006	US	10 MHz transducer	Forced flexion and extension	Manual examiner	Complete tear: >2 mm	Middle of the proximal phalanx	NT
Guntern et al. ³¹	2007	MRI	3 T with a dedicated wrist coil	Flexion and extension ^a	None	Complete tear: ≥2 mm	Mid-diaphysis level in sagittal plane	.88/1.0 Clinical exam
Bassemir et al. ²³	2015	US	18 MHz transducer	MCP: extension PIP: extension DIP: 30° flexion	500 g weight with custom sling	N/A	Level of proximal- to middle-third of the proximal phalanx	NT
Schneeberger & Schweizer ²⁴	2016	US	17.5 MHz transducer	MCP: extension PIP: 40° flexion DIP: 10° flexion Resting position	Manual NS ^c	Bowstringing	Middle of the proximal phalanx	NT
Reissner et al. ²⁵	2018	US	17 MHz transducer		None	Bowstringing	15 mm from the base of the proximal phalanx	NT
Hoff & Greenberg ³²	2018	MRI	1.5 T	Crimp grip	Subject grasped glass container	Complete tear: ≥2 mm	Middle of the proximal phalanx	NT
Schellhammer & Vantorre ³³	2019	MRI	1.5 T with a dedicated knee coil	6 consecutive finger positions from extension to full flexion	None	Bowstringing	Middle of the proximal phalanx	NT
Iruetagoiena-Urbieta et al. ²⁶	2020	US	24 MHz transducer	MCP: neutral PIP: 40° flexion DIP: 10° flexion	Manual Examiner	Complete tear: >2 mm	Middle of the proximal phalanx	NT
Scheibler, Janig, & Schweizer ²⁷	2021	US	NS	MCP: NS PIP: NS DIP: NS	Loading of the flexor tendon	NS	Middle of the proximal phalanx	NT

DIP, distal interphalangeal joint; FDP, flexor digitorum profundus; FDS, flexor digitorum superficialis; MCP, metacarpophalangeal joint; N/A, not applicable (not included in study); NS, not stated (not specified in study); NT, not taken; PIP, proximal interphalangeal joint; T, tesla; TP, tendon to phalanx distance.

^aWhen specific values for finger joints are not included, the information was not provided in the manuscript.
^bBowstringing = qualitative.
^cPerson applying resistance.
^dGold Standard used *reported as averages.

Figure 4. Ultrasound findings of a 21-year-old male rock climber with partial tear of the A2 pulley and tendinosis. **A**, Long axis image of the flexor digitorum tendons (T) and A2 pulley (arrow) demonstrating tendon thickening. **B**, Long axis image of tendons with notable hyperemia displayed on Doppler. **C**, SAX image exhibiting thickening of a relatively poorly defined tear of the A2 pulley (arrow) overlying the flexor tendons (T). Dist, distal.

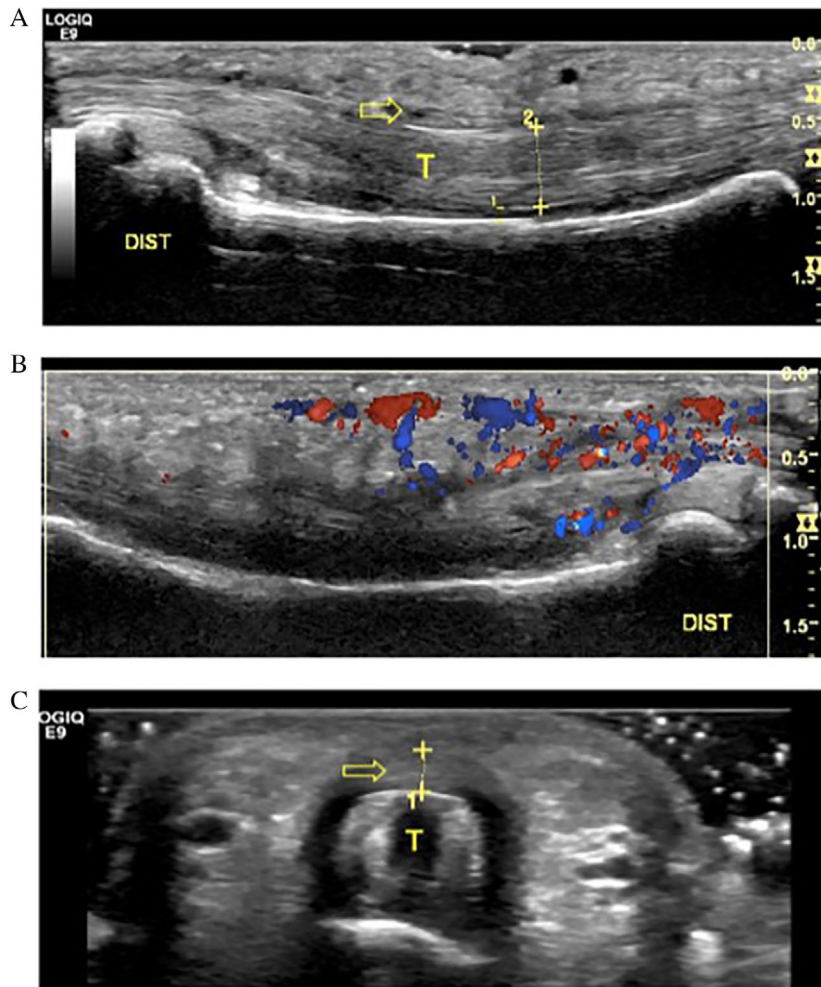
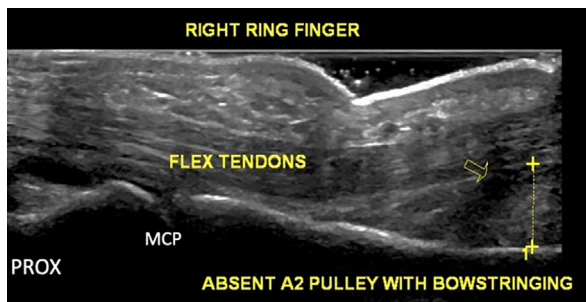


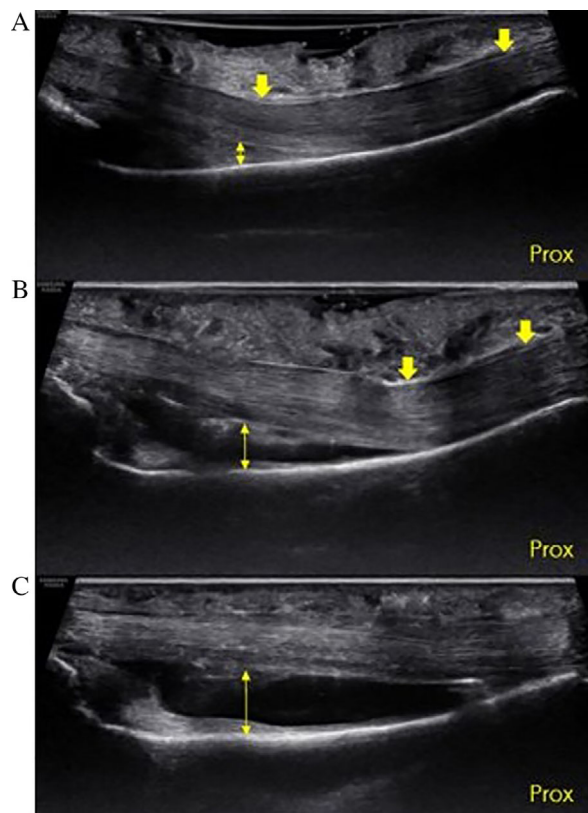
Figure 5. Example of bowstringing (arrow) in a patient with pulley injury. Long axis image of the flexor digitorum tendons demonstrates absence of the A2 pulley and a TP distance of 6.4 mm.



with surgical visualization of the tear, clinical diagnosis by physical examination, and/or dissection (see Table 2).

The majority of the 9 MRI studies varied in their methodology, with no standard position used to evaluate the pulleys. Five studies (56%) measured TP distance at the midpoint of the proximal phalanx without specifically describing how this was determined, 1 study (11%) measured at the level of the pulley, and 1 study (11%) measured the TP distance at the junction of the proximal two-thirds and at the distal one-third of the proximal phalanx. Four studies (44%) reported that qualitative bowstringing was

Figure 6. Ultrasound image of a cadaveric specimen. Long axis view of long finger showing the proximal–distal extent of the proximal phalanx (Prox, proximal). **A.** Intact A2 pulley (down arrows) in the crimp grip position using a gel standoff. Note how the superficial part of the tendons deflect at the distal end of A2, and the TP distance (double-headed arrow) is greater than 0 at distal A2 under normal conditions. **B.** Same specimen following US guided release of the distal 50% of A2 (down arrows). The point of tendon deflection has moved proximally, and the TP distance (double-headed arrow) has increased. **C.** Same specimen following US guided release 100% of A2. The bowstringing has increased and the tendon is completely separated from the palmar aspect of the phalanx (double-headed arrow).



seen on MRI, which was indicative of A2 pulley tears. The remaining 5 studies (56%) used TP distance of ≥ 2 mm as diagnostic criteria (note: one of these studies gave an average of 2.29 rather than a threshold of ≥ 2 mm).

Six studies (67%) performed provocative positioning or testing of the finger to stress the A2 pulley and accentuate bowstringing, whereas 3 studies (33%) did not apply any resistance. Of the 3 studies (33%) that reported degrees in flexion of the PIP

and DIP, PIP ranged from 40 to 60° and DIP was at 10°. The remaining 6 studies (67%) provided only qualitative descriptions of finger positioning (e.g., neutral, flexion, crimp grip).

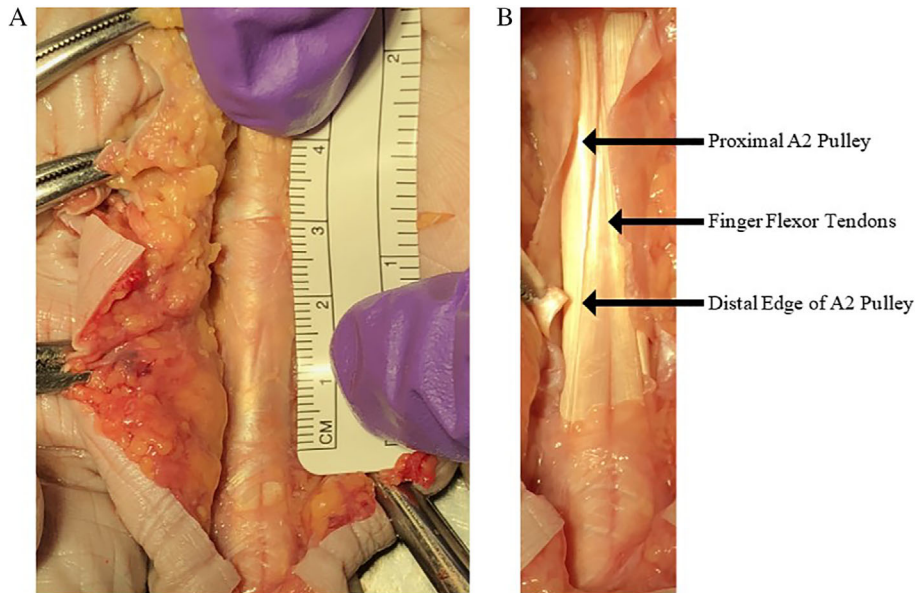
Computed Tomography (CT)

Only 2 studies were identified that utilized CT to evaluate the pulleys. One study (50%) was performed in cadavers and compared CT findings to that of US and MRI,¹⁵ and the other study (50%) was done in rock climbers and persons with miscellaneous injuries using CT only.³⁴ In the first study, Hauger and colleagues¹⁵ used cadavers and placed the PIP in 60° flexion and the DIP in 10° flexion, applied resistance using a 500 g weight with traction, and measured the TP distance at the junction of the proximal two-thirds and distal one-third of the proximal phalanx. In the second study, Le Viet and colleagues³⁴ studied rock climbers and persons with miscellaneous injuries with their PIPs flexed and DIPs extended. Manual resistance was applied and only qualitative bowstringing was reported. Neither study reported sensitivity and specificity against a gold standard. Specific diagnostic criteria are referenced in Table 2.

Discussion

The primary purpose of this review was to summarize the literature investigating the role of US to evaluate A2 pulley injuries, compare the accuracy of US versus MRI and CT when possible, and identify knowledge gaps to facilitate future research. Our review identified 22 studies investigating A2 pulley injuries with US (15 studies), MRI (9 studies), or CT (2 studies), with US being the most common used modality. Our review suggests that US is a superior method to visualize and diagnose A2 pulley injuries. Compared with US and MRI, CT was unable to directly visualize the pulleys and could only depict the gross morphology of the flexor tendons.¹⁵ Compared with CT, both US and MRI provide superior soft tissue imaging without ionizing radiation. Although US and MRI appear to be similarly accurate based on reported sensitivities and specificities,^{14,18,19,28,31,35} US is more accessible, less costly, allows easy side-to-side comparison, and facilitates dynamic assessment of the flexor-tendon–pulley system.¹³ Regardless of the type of imaging modality

Figure 7. Cadaveric image of the A2 pulley. **A**, The proximal fibers of A2 blend with the A1 pulley, creating a challenge in directly distinguishing the transition zone between the two pulleys. **B**, The arrows point to the proximal A2 pulley, flexor tendon, and the distal edge of the A2 pulley. Note that the leading edge is thickened in comparison to the proximal portion. The thinning of the proximal portion of the A2 pulley creates difficulty in identifying it with ultrasound imaging, a situation that can be improved with a high-frequency transducer.

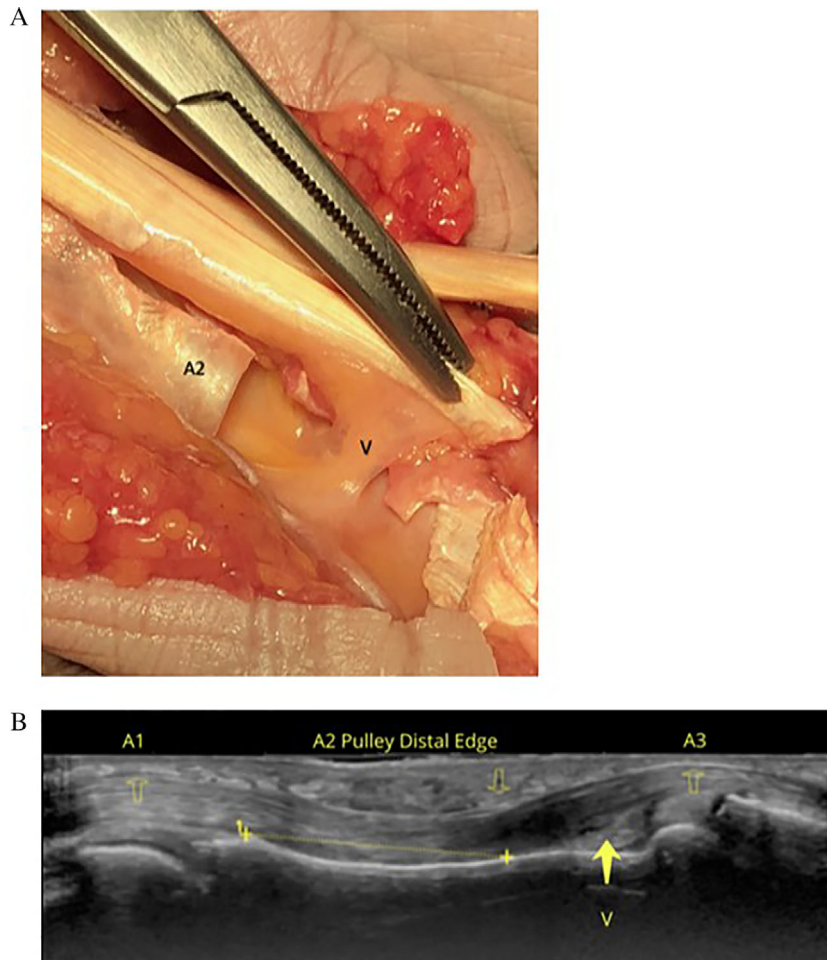


used (US, MRI, CT), we identified significant variability in the methods used to assess the A2 pulley with respect to hand/finger positioning, use of resistance, and diagnostic criteria. Nonetheless, some general statements can be made to summarize the findings in the currently available literature.

For positioning, the patient (or cadaveric specimen) was most often placed with the PIP in 40+ degrees of flexion and the DIP in 10° of flexion. Some amount of resistance to flexion was typically applied to place the pulley–tendon complex on tension and accentuate bowstringing. This resistance was applied using various methods but most frequently to the fingertip via pressure from the investigator. Resistance to flexion was most commonly performed in US studies, in which US provided the opportunity to dynamically assess and stress the flexor-tendon–pulley complex. It has been shown that the amount of force on the A2 pulley is directly proportional to the external force on the fingertip; therefore, resistance against the fingertip most closely resembles the mechanism of injury and increases sensitivity for the detection of bowstringing.¹¹ A form of resistance or stress testing was done in 14 of 15 US studies, 6 of 9 MRI studies, and 2 of 2 CT studies.

For diagnostics, some studies used more qualitative methods such as visualization of bowstringing (typically assessed in the longitudinal plane of the digit) or the presence of tenosynovitis, fluid surrounding the pulley (in particular when located posterior to the tendon), pulley thickening (assessed in the transverse plane), or the presence of cysts. Others directly measured the TP distance to quantify bowstringing. When TP distance was measured, the site of measurement varied significantly across studies but was most commonly located at the midpoint of the proximal phalanx. Determination of how the midpoint was identified, however, was never well defined (e.g., tip of the distal phalanx to tip of proximal phalanx). Sensitivity and specificity values were only reported for a portion of the US (27%) and MRI (33%) studies, but generally reflected high accuracy for diagnosing A2 pulley tears, based on MRI, surgical, clinical, and cadaveric gold standards. Of potential clinical relevance, lowest sensitivity and specificity values were reported by studies in which the hand and fingers were placed in a neutral position, while the higher values occurred in studies that placed the hand and fingers in crimp grip position (which included resistance to flexion).²⁸

Figure 8. Intact vinculum. **A.** Cadaveric image depicting the vinculum (V). Note its relationship to the A2 pulley. **B.** Image **B** is a longitudinal ultrasound image with an 18 MHz transducer depicting the A2 pulley over the proximal phalanx with the flexor tendons underneath. The A1 and A3 pulleys are also depicted in the image demonstrating the anatomical relationship to the region of the vinculum.



Interestingly, although the full crimp grip produces the highest stress on the A2 pulley,³⁷ none of the US studies to date have used this position to evaluate the A2 pulley (Figure 6). Future US investigations should consider utilizing the full crimp position to evaluate A2 pulley injuries.

Based on our literature review, there is a need for standardizing positioning and measurement prior to further defining the role of diagnostic imaging in A2 pulley injuries. This is particularly the case with respect to US because US provides the opportunity to place the hand and fingers in multiple different positions. However, choosing the best site at which to measure the pulley remains challenging. The proximal edge of the A2 pulley is difficult to evaluate due to its

proximity to (and sometimes confluence with) the A1 pulley and its relative thinness compared to the distal edge (Figure 7). Directly evaluating the distal edge of the A2 pulley can be problematic given its high anatomic variability, as there is a difference in the location of the A2 pulley in relation to where the ulnar and radial slips of the flexor digitorum superficialis diverge. In addition, we hypothesize that an intact vinculum (Figure 8) may contribute to a false-negative evaluation of bowstringing or TP distance, although this has not yet been described. It is possible that with advancements in technology and the use of higher-frequency transducers and higher Tesla MRI machines that clinicians may be able to better visualize these given structures.

With enhanced imaging, diagnostics may not rely on indirect signs of rupture with measurement discrepancies, but rather direct visualization. Future research is warranted to determine how finger position and point of measurement impact outcomes in defining the ideal method for assessment.

It is important to refine the diagnosis of A2 pulley injuries because detection and characterization of these injuries determine treatment. In general, prognosis and treatment options are based on the number (A2 versus combined) and severity of injured pulleys. Consequently, accurate diagnosis is a prerequisite for triage. Our review has revealed that relatively few studies provide defined cutoff values for TP distance to assist clinicians with this decision-making. For example, Hauger and colleagues described a partial A2 pulley tear as a TP distance of 0–3 mm, complete tear 2–5 mm, and combination tear of multiple pulleys 5–8 mm for both US and MRI based on simulated lesions in a cadaver model.¹⁵ A similar definition was used in an US study by Klauser et al. in which a partial A2 tear was defined as <3 mm and a complete tear as ≥3 mm, using MRI as a gold standard.¹⁴ However, in an US study by Schoffl and colleagues, >2 mm identified a complete tear based on a cadaver model,¹⁹ and an MRI study by Bodner et al. allowed up to 5 mm of TP distance before diagnosing a complete tear.³⁵ As previously discussed, it is highly likely that methodological differences account for the majority of the differences in diagnostic criteria published in the literature. This situation presents both a challenge and an opportunity for future research to systematically determine the standards of evaluation.

Conclusion

The results of this review suggest that US should be used as the primary imaging modality to assess A2 pulley injuries due to its high accuracy, relatively low cost, ease of access, and dynamic imaging capabilities. Furthermore, manually resisted flexion is likely beneficial to stress the A2 pulley and accentuate bowstringing. Future research should determine the best positions in which to qualitatively and quantitatively evaluate the A2 pulley to assist clinicians in appropriate triage of isolated and combined A2 pulley injuries.

References

- Smith J, Rizzo M, Lai JK. Sonographically guided percutaneous first annular pulley release: cadaveric safety study of needle and knife techniques. *J Ultrasound Med* 2010; 29:1531–1542.
- Heithoff SJ, Millender LH, Helman J. Bowstringing as a complication of trigger finger release. *J Hand Surg Am* 1988; 13:567–570.
- Crowley TP. The flexor tendon pulley system and rock climbing. *J Hand Microsurg* 2012; 4:25–29.
- Rohrbough JT, Mudge MK, Schilling RC. Overuse injuries in the elite rock climber. *Med Sci Sports Exerc* 2000; 32:1369–1372.
- Lourie GM, Hamby Z, Raasch WG, Chandler JB, Porter JL. Annular flexor pulley injuries in professional baseball pitchers: a case series. *Am J Sports Med* 2011; 39:421–424.
- Patel P, Schucany WG, Toye L, Ortinau E. Flexor tendon pulley injury in a bowler. *Proc (Bayl Univ Med Cent)* 2012; 25:282–284.
- Dowd MB, Fuentes EO. Closed traumatic A2 pulley rupture: rare mechanism of injury. *J Hand Surg Eur Vol* 2009; 34:548–549.
- Gyuricza C, Umoh E, Wolfe SW. Multiple pulley rupture following corticosteroid injection for trigger digit: case report. *J Hand Surg Am* 2009; 34:1444–1448.
- Manske PR, Lesker PA. Strength of human pulleys. *Hand* 1977; 9:147–152.
- El-Sheikh Y, Wong I, Farrokhyar F, Thoma A. Diagnosis of finger flexor pulley injury in rock climbers: a systematic review. *Can J Plast Surg* 2006; 14:227–231.
- Schweizer A. Biomechanical properties of the crimp grip position in rock climbers. *J Biomech* 2001; 34:217–223.
- Vigouroux L, Quaine F, Labarre-Vila A, Moutet F. Estimation of finger muscle tendon tensions and pulley forces during specific sport-climbing grip techniques. *J Biomech* 2006; 39:2583–2592.
- Bianchi S, Martinoli C, de Gautard R, Gaignot C. Ultrasound of the digital flexor system: Normal and pathological findings. *J Ultrasound* 2007; 10:85–92.
- Klauser A, Frauscher F, Bodner G, et al. Finger pulley injuries in extreme rock climbers: depiction with dynamic US. *Radiology* 2002; 222:755–761.
- Hauger O, Chung CB, Lektrakul N, et al. Pulley system in the fingers: normal anatomy and simulated lesions in cadavers at MR imaging, CT, and US with and without contrast material distention of the tendon sheath. *Radiology* 2000; 217:201–212.
- Jacobson JA. Musculoskeletal ultrasound and MRI: which do I choose? *Semin Musculoskelet Radiol* 2005; 9:135–149.
- Leefflang S, Coert JH. The role of proximal pulleys in preventing tendon bowstringing: pulley rupture and tendon bowstringing. *J Plast Reconstr Aesthet Surg* 2014; 67:822–827.
- Schöffl I, Hugel A, Schöffl V, Rascher W, Jüngert J. Diagnosis of complex pulley ruptures using ultrasound in cadaver models. *Ultrasound Med Biol* 2017; 43:662–669.

19. Schöffl I, Deeg J, Lutter C, Bayer T, Schöffl V. Diagnosis of A3 pulley injuries using ultrasound. *Sportverletz Sportschaden* 2018; 32: 251–259.
20. Klauser A, Bodner G, Frauscher F, Gabl M, Zur ND. Finger injuries in extreme rock climbers. Assessment of high-resolution ultrasonography. *Am J Sports Med* 1999; 27:733–737.
21. Klauser A, Frauscher F, Bodner G, et al. Value of high-resolution ultrasound in the evaluation of finger injuries in extreme sport climbers. *Ultraschall Med* 2000; 21:73–78.
22. Schöffl VR, Einwag F, Strecker W, Schöffl I. Strength measurement and clinical outcome after pulley ruptures in climbers. *Med Sci Sports Exerc* 2006; 38:637–643.
23. Bassemir D, Unglaub F, Hahn P, Müller LP, Bruckner T, Spies CK. Sonographical parameters of the finger pulley system in healthy adults. *Arch Orthop Trauma Surg* 2015; 135:1615–1622.
24. Schneeberger M, Schweizer A. Pulley ruptures in rock climbers: outcome of conservative treatment with the pulley-protection splint—a series of 47 cases. *Wilderness Environ Med* 2016; 27:211–218.
25. Reissner L, Zechmann-Mueller N, Klein HJ, Calcagni M, Giesen T. Sonographic study of repair, gapping and tendon bowstringing after primary flexor digitorum profundus repair in zone 2. *J Hand Surg Eur Vol* 2018; 43:480–486.
26. Iruretagoiena-Urbieta X, De la Fuente-Ortiz de Zarate J, Blasi M, Obradó-Carriedo F, Ormazabal-Arístegui A, Rodríguez-López ES. Grip force measurement as a complement to high-resolution ultrasound in the diagnosis and follow-up of A2 and A4 finger pulley injuries. *Diagnostics (Basel)* 2020; 10:206. <https://doi.org/10.3390/diagnostics10040206>.
27. Scheibler AG, Janig C, Schweizer A. Primarily conservative treatment for triple (A2-A3-A4) finger flexor tendon pulley disruption. *Hand Surg Rehabil* 2021; 40:314–318.
28. Bayer T, Fries S, Schweizer A, Schöffl I, Janka R, Bongartz G. Stress examination of flexor tendon pulley rupture in the crimp grip position: a 1.5-tesla MRI cadaver study. *Skeletal Radiol* 2015; 44:77–84.
29. Parellada JA, Balkissoon AR, Hayes CW, Conway WF. Bowstring injury of the flexor tendon pulley system: MR imaging. *AJR Am J Roentgenol* 1996; 167:347–349.
30. Gabl M, Rangger C, Lutz M, Fink C, Rudisch A, Pechlaner S. Disruption of the finger flexor pulley system in elite rock climbers. *Am J Sports Med* 1998; 26:651–655.
31. Guntern D, Goncalves-Matoso V, Gray A, Picht C, Schnyder P, Theumann N. Finger A2 pulley lesions in rock climbers: detection and characterization with magnetic resonance imaging at 3 tesla—initial results. *Invest Radiol* 2007; 42:435–441.
32. Hoff MN, Greenberg TD. MRI sport-specific pulley imaging. *Skeletal Radiol* 2018; 47:989–992.
33. Schellhammer F, Vantorre A. Semi-dynamic MRI of climbing-associated injuries of the finger. *Skeletal Radiol* 2019; 48: 1435–1437.
34. Le Viet D, Rousselin B, Roulot E, Lantieri L, Godefroy D. Diagnosis of digital pulley rupture by computed tomography. *J Hand Surg Am* 1996; 21:245–248.
35. Bodner G, Rudisch A, Gabl M, Judmaier W, Springer P, Klauser A. Diagnosis of digital flexor tendon annular pulley disruption: comparison of high frequency ultrasound and MRI. *Ultraschall Med* 1999; 20:131–136.
36. Martinoli C, Bianchi S, Nebiolo M, Derchi LE, Garcia JF. Sonographic evaluation of digital annular pulley tears. *Skeletal Radiol* 2000; 29:387–391.
37. Schöffl I, Oppelt K, Jüngert J, Schweizer A, Neuhuber W, Schöffl V. The influence of the crimp and slope grip position on the finger pulley system. *J Biomech* 2009; 42:2183–2187.